

Current Concepts

The Disabled Throwing Shoulder: Spectrum of Pathology Part I: Pathoanatomy and Biomechanics

Stephen S. Burkhart, M.D., Craig D. Morgan, M.D., and W. Ben Kibler, M.D.

Prologue: Several years ago, when we began to question microinstability as the universal cause of the disabled throwing shoulder, we knew that we were questioning a sacrosanct tenet of American sports medicine. However, we were comfortable in our skepticism because we were relying on arthroscopic insights, clinical observations, and biomechanical data, thereby challenging unverified opinion with science. In so doing, we assembled a unified concept of the disabled throwing shoulder that encompassed biomechanics, pathoanatomy, kinetic chain considerations, surgical treatment, and rehabilitation. In developing this unified concept, we rejected much of the conventional wisdom of microinstability-based treatment in favor of more successful techniques (as judged by comparative outcomes) that were based on sound biomechanical concepts that had been scientifically verified. Although we have reported various components of this unified concept previously, we have been urged by many of our colleagues to publish this information together in a single reference for easy access by orthopaedic surgeons who treat overhead athletes. We are grateful to the editors of *Arthroscopy* for allowing us to present our view of the disabled throwing shoulder. Part I: Pathoanatomy and Biomechanics is presented in this issue. Part II: Evaluation and Treatment of SLAP Lesions in Throwers will be presented in the May-June issue. Part III: The “SICK” Scapula, Scapular Dyskinesis, the Kinetic Chain, and Rehabilitation will be presented in the July-August issue. We hope you find it thought-provoking and compelling.

The medical community’s fascination with the disabled throwing shoulder derives from the public’s fascination with the intact throwing shoulder. The ability to throw a baseball with pinpoint accuracy at speeds above 90 miles an hour defines the upper echelon of athletic achievement. The sudden loss of that ability, as occurs in the so-called “dead arm,” is nothing short of an athletic tragedy.

The dead arm has long been recognized as a career-ending affliction in the overhead athlete, but only recently have we understood this condition enough to provide effective treatment. We define the “dead arm”

as any pathologic shoulder condition in which the thrower is unable to throw with preinjury velocity and control because of a combination of pain and subjective unease in the shoulder. The athlete usually relates the discomfort to the late cocking or early acceleration phase of the throwing sequence, when the arm begins to move forward. At this point, the thrower feels a sudden sharp pain, the arm “goes dead,” and the athlete is unable to throw the ball with his usual velocity. The story of the dead arm is the story of the disabled throwing shoulder; we examine that story, in all its forms, in this 3-part Current Concepts series.

SLAP LESIONS AS A CAUSE OF THE DEAD ARM

Two of the authors (C.D.M., S.S.B.) reported on 53 baseball players, 44 of whom were pitchers, who had type 2 SLAP lesions that were surgically repaired after

Address correspondence and reprint requests to Stephen S. Burkhart, M.D., 540 Madison Oak Dr, Suite 620, San Antonio, TX 78258, U.S.A.

© 2003 by the Arthroscopy Association of North America
0749-8063/03/1904-3489-1\$30.00/0
doi:10.1053/jars.2003.50128

nonresponse to nonoperative treatment.^{1,2} All the type 2 SLAP lesions were located over the posterosuperior quadrant of the glenoid (posterior SLAP) or over the posterosuperior and anterosuperior quadrants (combined anteroposterior SLAP) (Fig 1). Arthroscopic repair of these type 2 SLAP lesions returned 87% of these athletes to the preinjury level of performance and velocity.

One must recognize that, historically, the cause of the dead arm has been somewhat mysterious and elusive. It was variously characterized as a disorder caused by psychopathology,³ posterior glenoid calcifications,^{4,5} acromial osteophytes,⁶ coracoacromial ligament impingement,^{7,8} rotator cuff problems,⁹ biceps tendinitis,¹⁰ acromioclavicular joint dysfunction,¹¹ microinstability,^{12,13} internal impingement,^{14,15} and SLAP lesions.^{1,2,15-19}

Tibone et al.⁶ evaluated the results of open acromioplasty in throwing athletes and found that only 22% returned to their preinjury levels of competition. Jobe et al.¹³ described impingement-instability overlap. They postulated that repetitive throwing gradually stretches out the anterior capsuloligamentous complex, allowing anterosuperior migration of the humeral head during throwing, thus causing subacromial impingement symptoms and the inability to throw hard. They reported some success with open capsulolabral reconstruction (50% return to pitching for one season or more in a report of 12 pitchers), but indications for this procedure were vague.²⁰ A later report on capsulolabral reconstruction by Rubenstein et al.²¹ stated that 77% of 22 pitchers were able to return to pitching for at least one season, but that only 15 of the 22 pitchers (68%) had an excellent result.

Andrews et al.¹⁰ first observed anterosuperior glenoid labrum tears in throwing athletes and arthro-

scopically debrided them. Snyder et al.¹⁷ subsequently described SLAP lesions in the general population, but did not specifically relate them to overhead athletes.

Our clinical experience with the dead arm syndrome has confirmed our hypothesis that SLAP lesions are the most common pathologic entities associated with this problem.^{1,2,19} Our 87% rate of successful return to preinjury performance levels for 2 seasons or more in throwers¹ is much higher than the reported success rate of open anterior capsulolabral repairs (50% to 68% return to previous sport for one season or more, with no criteria for performance level).^{20,21} Furthermore, we believe that the pseudolaxity associated with SLAP lesions has led to the erroneous diagnosis of microinstability in many cases, prompting ill-advised instability surgery in patients who had unrecognized SLAP lesions that went unrepaired. We suspect that the reason that capsulolabral repair ever worked is that it serendipitously tightened the anterior structures to "match" the pathologic tightness of the posteroinferior capsule present in throwing athletes with SLAP lesions. We also suspect that postoperative rehabilitation stretched the anterior and posterior structures equally, thereby allowing a return to more normal throwing mechanics.

Internal Impingement

Walch et al.¹⁴ described internal impingement as an intra-articular impingement that occurs in all shoulders in the abducted externally rotated position. In this 90°-90° position, the undersurface of the posterosuperior rotator cuff contacts the posterosuperior glenoid labrum and may become pinched between the labrum and greater tuberosity (Fig 2). Jobe¹⁵ applied this observation to the throwing athlete and described an

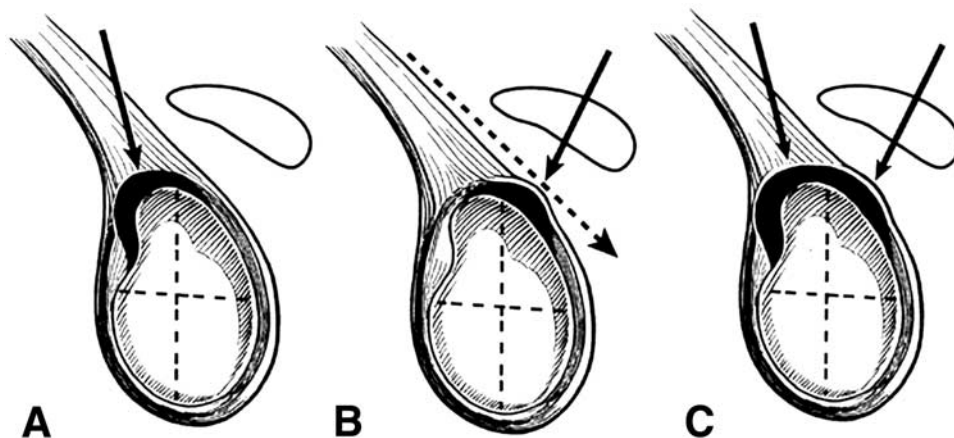


FIGURE 1. Three subtypes of type 2 SLAP lesions, designated by anatomic location: (A) anterior, (B) posterior, and (C) combined anteroposterior.

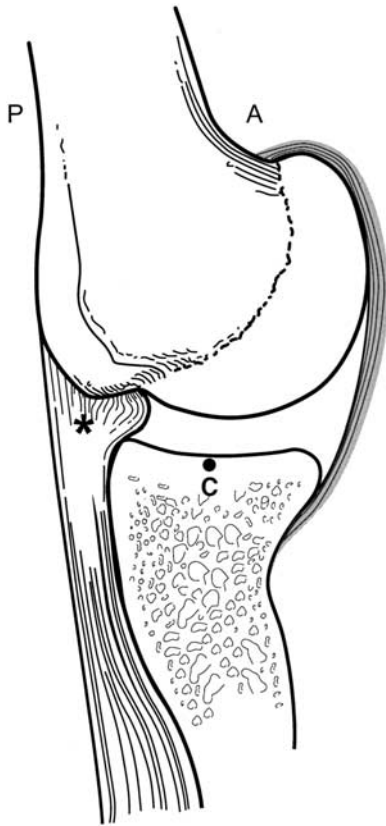


FIGURE 2. In abduction and external rotation of the shoulder, the greater tuberosity abuts against the posterosuperior glenoid, entrapping the rotator cuff between the 2 bones. (*) This has been dubbed internal impingement. (A, anterior; P, posterior; C, glenohumeral center of rotation.)

expanded spectrum of injury to the rotator cuff, glenoid labrum, and even bone. He also hypothesized that the internal impingement in throwers might progressively worsen because of gradual repetitive stretching of the anterior capsuloligamentous structures. This theory of anterior microinstability aggravating internal impingement lent credence initially to treating this problem using anterior capsulolabral reconstruction, although the results of this treatment for throwing athletes were unpredictable.^{20,21}

Halbrecht et al.²² disagreed with this premise of anterior instability aggravating internal impingement and showed that an unstable shoulder that is subluxed anteriorly will have less contact with the posterosuperior glenoid (internal impingement) than it has in the reduced position. Instead of worsening internal impingement, Halbrecht et al.²² discovered that anterior instability would lessen it, thereby casting doubt on

Jobe's premise of instability as a pathologic culprit. We explain in this review why we believe that internal impingement is a normal phenomenon in all shoulders and is not usually a part of the pathology in the disabled throwing shoulder.

THE ROLE OF THE POSTEROINFERIOR CAPSULE: POSTEROINFERIOR CAPSULAR CONTRACTURE WITH RESULTANT GLENOHUMERAL INTERNAL ROTATION DEFICIT AND ITS RELATIONSHIP TO SUPERIOR INSTABILITY AND SLAP LESIONS

For many years, researchers have documented that the throwing shoulder acquires increased external rotation in abduction over time compared with the nonthrowing shoulder.^{15,20,23-26} As an adaptive phenomenon, this increase in external rotation has been attributed by some authors to repetitive "microtrauma" to the anterior capsule produced in the cocking phase of throwing. If excessive, this microtrauma produces symptomatic anterior instability and presents as the dead arm syndrome.^{15,20,23-26} We believe that any stretching of the anterior structures that occurs is on the basis of hyperexternal rotation and hyperhorizontal abduction, rather than a true anterior instability pattern. We believe that the most important pathologic process that occurs in throwers is a loss of internal rotation in abduction. In symptomatic throwing shoulders, this loss far exceeds the external rotation gain.²⁷ We propose that an acquired internal rotation loss caused by a posteroinferior capsular contracture is the essential lesion that secondarily results in increased external rotation. This can be with or without anterior capsular stretching, which may occur as a tertiary problem.^{19,27,28}

Glenohumeral internal rotation deficit (GIRD) is defined as the loss in degrees of glenohumeral internal rotation of the throwing shoulder compared with the nonthrowing shoulder. By convention, glenohumeral rotation is measured with the patient supine, the shoulder abducted 90° in the plane of the body, and the scapula stabilized against the examination table by downward pressure applied by the examiner to the anterior aspect of the shoulder (Fig 3). Alternatively, the examiner may stabilize the scapula with the patient sitting. Using these methods, internal and external rotation is measured with a goniometer to the point of glenohumeral rotation where the scapula just starts to move on the posterior chest wall.

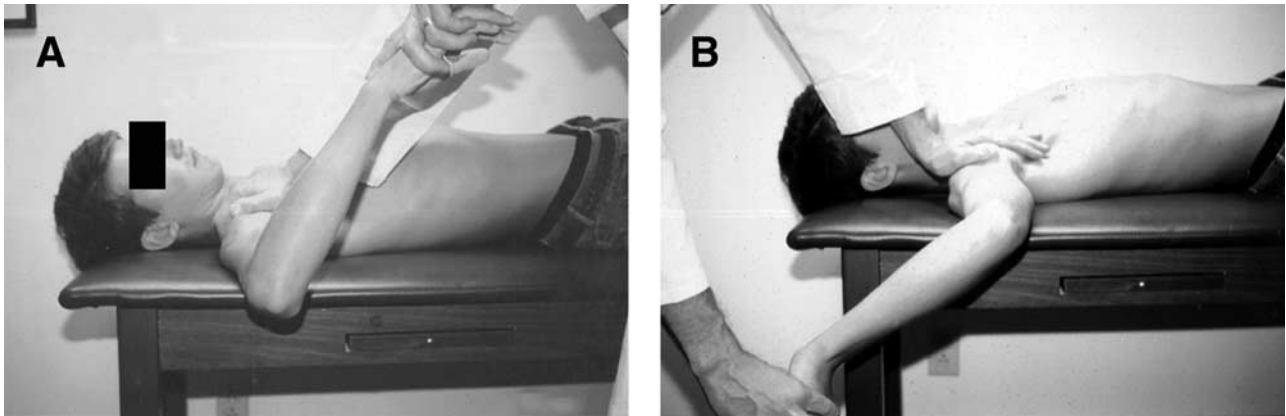


FIGURE 3. (A) Internal rotation is measured with the patient's shoulder in 90° abduction and the elbow in 90° flexion while the examiner stabilizes the scapula. The endpoint of internal rotation is taken as the point at which the scapula begins to rotate posteriorly. (B) External rotation is also measured while stabilizing the scapula. Note that the neutral position (0°) is that in which the forearm is perpendicular to the patient's body (12 o'clock position in the supine patient).

A series of 124 baseball pitchers with arthroscopically proven symptomatic type 2 SLAP lesions treated by one of the authors (C.D.M.) all had preoperative severe GIRD in their throwing shoulders. In this group, which included 40 professional, 43 college, and 41 high school pitchers, the average GIRD was 53° with a range from 25° to 80°. These findings are particularly striking when compared with an average GIRD of only 13° preseason and 16° postseason found in 19 asymptomatic dominant shoulders of professional baseball pitchers measured during spring training and at the end of the 2000 major league baseball season (P. Donley, J. Cooper, personal communication, November 2000).

Others researchers have reported similar findings regarding the association of GIRD with the development of shoulder problems in the overhead throwing athlete. In 1991, Verna²⁷ was the first to recognize the relationship of GIRD with shoulder dysfunction in the throwing athlete. He followed up 39 professional pitchers during a single baseball season. These pitchers were identified at spring training to have 25° or less of total internal rotation (GIRD, 35° or more in each of these pitchers) and found that 60% developed shoulder problems requiring them to stop pitching during the study period.

Similarly, one of the authors (W.B.K.),²⁹ in a series of 38 arthroscopically proven symptomatic type 2 SLAP lesions in overhead athletes, found significant GIRD in all cases (average GIRD, 33°; range, 26° to 58°). In another study, the same author (W.B.K.)³⁰ prospectively evaluated high-level tennis players followed up for 2 years who were divided into 2 groups.

One group performed daily posterior inferior capsular stretching to minimize GIRD, and the other (control) group did not stretch. Over the 2-year study period, those who stretched significantly increased internal rotation and total rotation compared with the control group. In addition, those in the stretching group had a 38% decrease in the incidence of shoulder problems compared with the control group.

Finally, Cooper manually stretched 22 major league level pitchers daily to minimize GIRD to less than 20° during the 1997, 1998, and 1999 professional baseball seasons (J. Cooper, personal communication, December 1999). During those seasons, he reported no innings lost, no intra-articular problems, and no surgical procedures in the study group. These reports clearly establish that a prophylactic focused posteroinferior capsular stretching program is successful in minimizing GIRD and is effective in preventing secondary intra-articular problems, particularly posterior type 2 SLAP lesions.

In our experience, approximately 90% of all throwers with symptomatic GIRD (greater than 25°) will respond positively to a compliant posteroinferior capsular stretching program and reduce GIRD to an acceptable level. An acceptable level is defined as (1) less than 20° or (2) less than 10% of the total rotation seen in the nonthrowing shoulder. This goal can usually be accomplished over 2 weeks with the use of "sleeper stretches" (Fig 4).

Conversely, 10% of throwers do not respond to stretching. These individuals tend to be older elite pitchers who have been throwing for years, from little league to major league. Those who fail the stretching

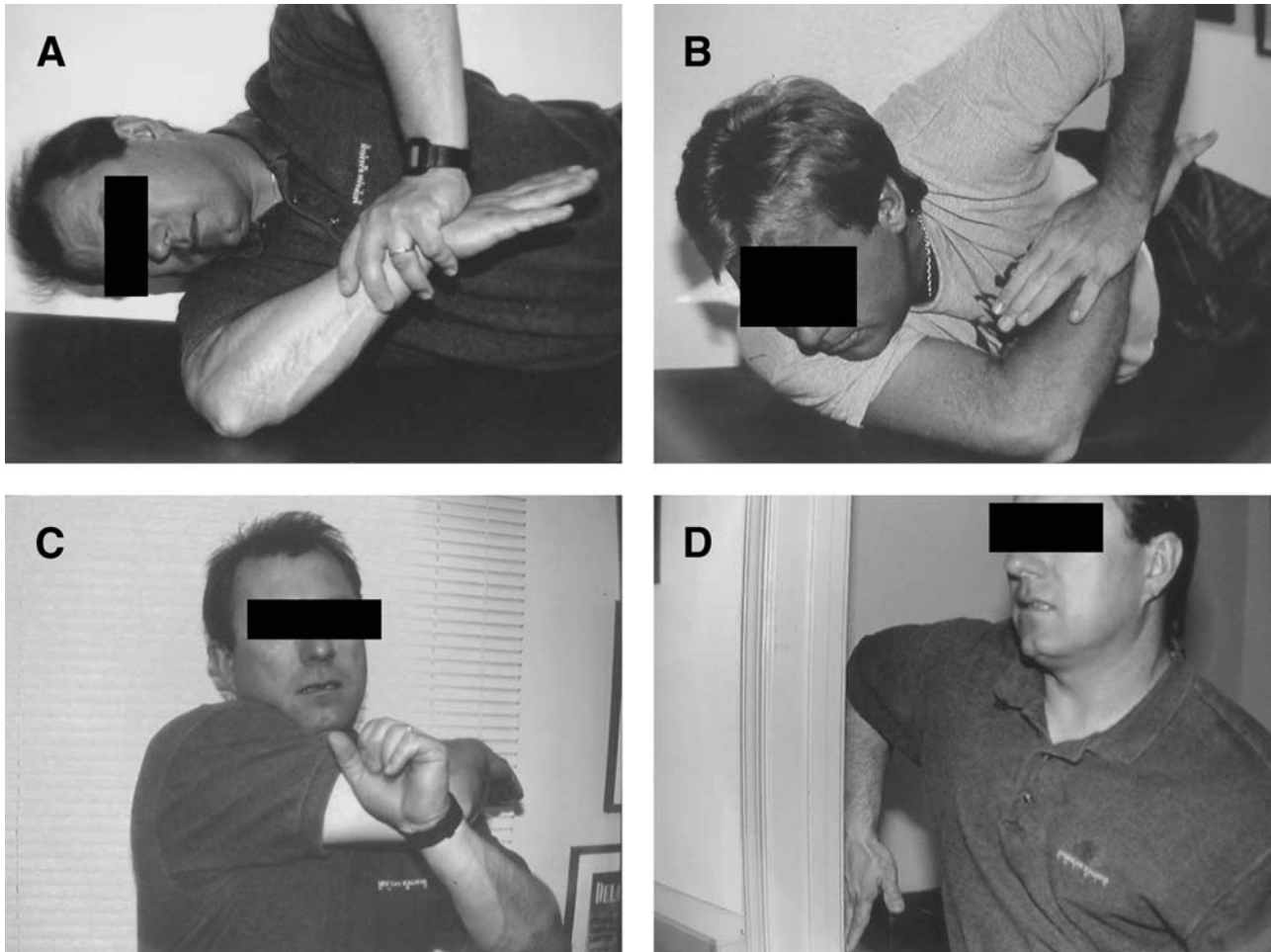


FIGURE 4. Focused posterior inferior capsular stretches. (A) In the sleeper stretch, the patient is side lying with the scapula stabilized against a wall, the shoulder flexed 90° , and the elbow flexed 90° . Passive internal rotation to the arm is applied by the nondominant arm to the dominant wrist. (B) The roll-over sleeper stretch is the same as the sleeper stretch except that the shoulder is only flexed 50° to 60° and the patient rolls forward 30° to 40° from vertical side lying. (C) The cross-arm stretch has the patient standing with the shoulder flexed 90° and passive adduction applied by the nondominant arm to the dominant elbow. This traditional posterior stretch primarily stretches the posterior musculature to a greater degree than the posterior inferior capsule. It is imperative that the other stretches in this sequence be done as well. (D) In the doorway stretch, shoulder is abducted 90° and the elbow flexed 90° with the elbow on the edge of an open doorway. The patient leans forward and inferior to apply an inferior capsular stretch to the shoulder.

program tend to be on the severe end of the GIRD spectrum and to have had chronic long-standing symptoms usually associated with intra-articular pathology (type 2 posterior SLAP lesions). Patients who do not respond to stretch have been treated by one author (C.D.M.) with an arthroscopic selective posteroinferior capsulotomy, which in most instances is performed concomitantly with SLAP lesion repair (Fig 5).

Typical arthroscopic findings in these patients include a severely contracted and thickened posteroinferior recess and capsule in the zone of the posterior band of the inferior glenohumeral liga-

ment (IGHL) complex (Fig 6). In most cases, the capsule in this zone will be found to be 6 mm thick or more. If a selective posteroinferior capsulotomy is performed, one can expect an immediate 65° increase in glenohumeral internal rotation (Fig 5). This must be maintained by an immediate postoperative internal rotation stretching program to prevent the capsulotomy gap from closing during the healing phase. It is important to understand that it is extremely unusual for high school and college pitchers to be nonresponsive to stretching. We have rarely needed selective posteroinferior capsulotomy in these younger pitchers.

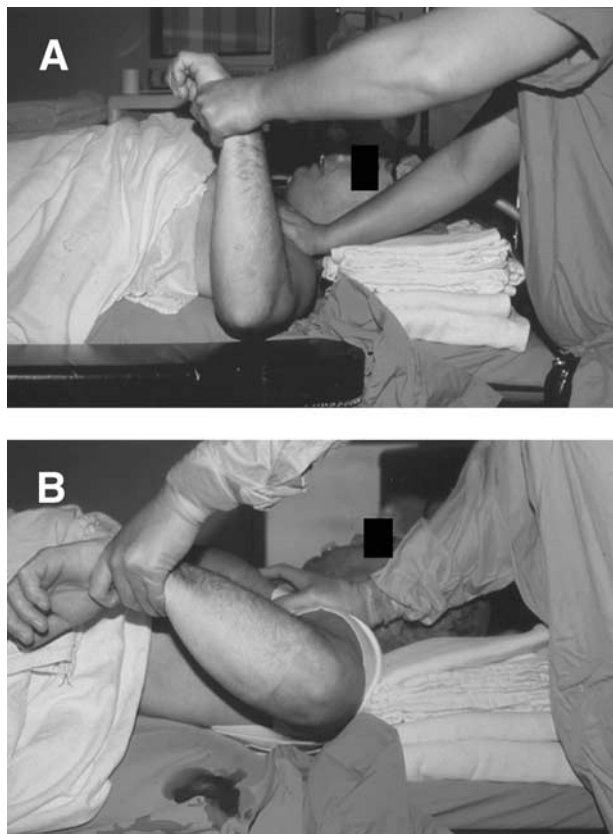


FIGURE 5. A professional left-handed baseball pitcher with a type 2 SLAP lesion and severe GIRD that was nonresponsive to stretch. Examination under anesthesia revealed no (0°) internal rotation prior to arthroscopy, and 65° of internal rotation after a selective posteroinferior capsulotomy and type 2 SLAP lesion repair.

The Tethered Shoulder: The Reciprocal Cable Model and the Cam Effect

O'Brien et al.³¹ popularized the concept of the IGHL complex, bounded by an anterior band and posterior band, performing like a hammock to support the humeral head when the arm is in abduction (Fig 7). One must remember that throwing is a dynamic activity, and the position of a given structure will continually shift during the throwing cycle. For example, in full abduction and external rotation (the cocked position), the posterior band of the IGHL is below the humeral head. If the posterior band is contracted, it will exert a posterosuperior force on the humeral head. From a mechanical standpoint, this hammock model of the IGHL complex can be simplified even further so that the IGHL complex is represented by 2 dominant structural components, the anterior band and the posterior band, functioning as interdependent cables (Fig 8).

In this model, the primary passive constraints of the glenohumeral joint can be represented simply as a system composed of 2 cables that develop tension reciprocally and equally as the shoulder internally and externally rotates in the 90° abducted position. The glenoid serves as a tension ring for the cables as they span the distance from their humeral attachments to the glenoid.³² This reciprocal cable model defines the allowable “envelope of motion” of the shoulder in

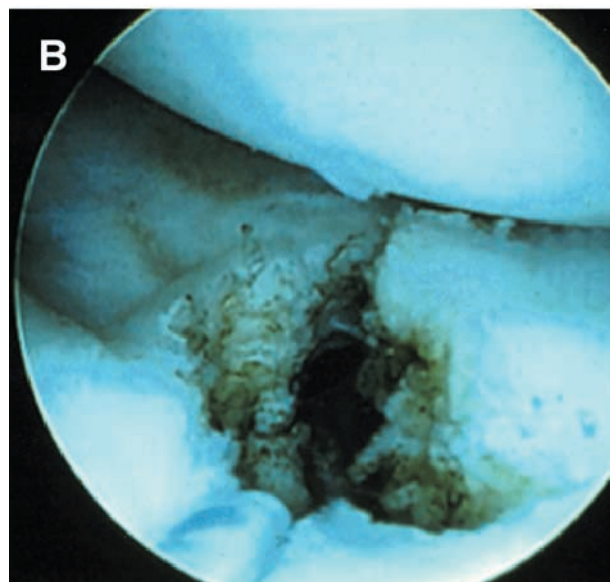
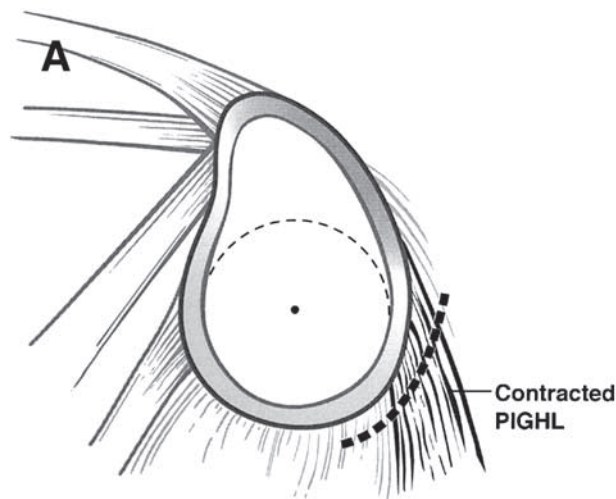


FIGURE 6. Selective posteroinferior capsulotomy. (A) The capsular contracture is located in the posteroinferior quadrant of the capsule in the zone of the posterior band of the IGHL complex. The capsulotomy is made ¼ inch away from the labrum from the 9 or 3 o'clock position to the 6 o'clock position. (B) On arthroscopic inspection after the capsulotomy is made, note how thick the capsule in this zone has become.

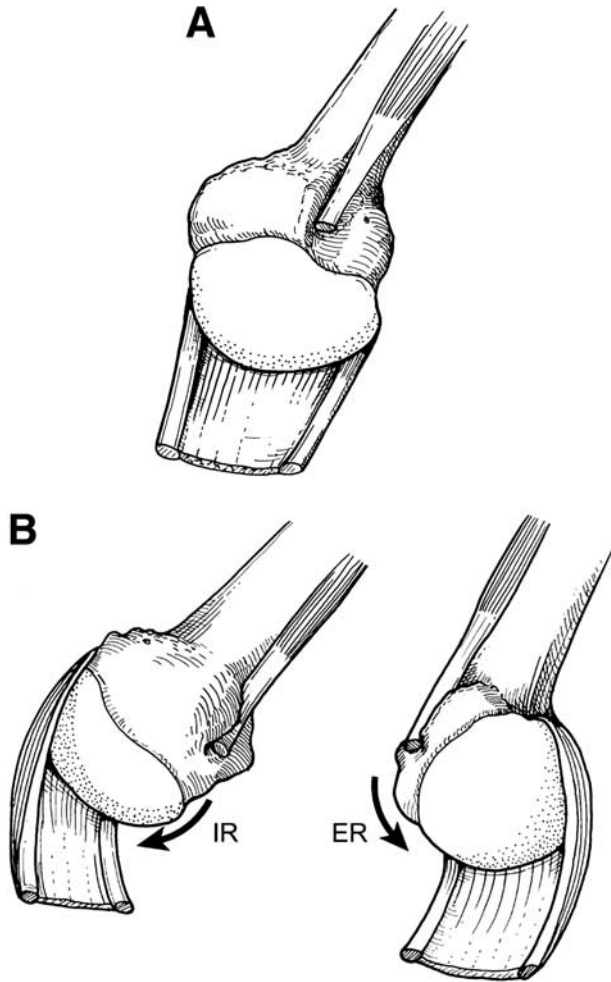


FIGURE 7. The normal hammock effect of the anterior and posterior bands of the IGHL complex described by O'Brien et al.³¹ permits (A) a balanced axillary pouch to direct internal rotation (IR) and external rotation (ER) of the humeral head in abduction (B) around a relatively fixed central glenoid rotation point.

much the same way that the 4-bar linkage model defines allowable knee motion based on cruciate restraints.^{33,34} With external rotation of the humerus about its central contact point on the glenoid (the glenoid "bare spot"), the cables tighten and develop tension equally as they assume an oblique course across their allowable envelope of motion (Fig 9).

If the posterior cable is shortened, simulating a contracted posterior band, it acts as a tether, shifting the glenohumeral contact point posterosuperiorly during combined abduction and external rotation (Fig 10). This shift occurs because the shortened posterior cable reaches its maximum elongation with glenohumeral external rotation before the anterior cable max-

imally elongates so that the anterior band is still permitting external rotation anteriorly even though the posterior band is tethering the shoulder from its location beneath the humeral head, where it also exerts a posterosuperior force on the humerus. Because the arc of motion of the greater tuberosity has now shifted posterosuperiorly, it no longer abuts against the usual segment of the posterosuperior glenoid in combined abduction and external rotation, and additional external rotation can be obtained.

Furthermore, the cam effect of the humeral head and the proximal humeral calcar on the anteroinferior capsule is reduced by that shift, because the anteroinferior capsule is no longer tightly draped across the calcar after the shift occurs (Fig 11). In this way, by a posterosuperior shift of the glenohumeral contact point, hyperexternal rotation is preserved and even

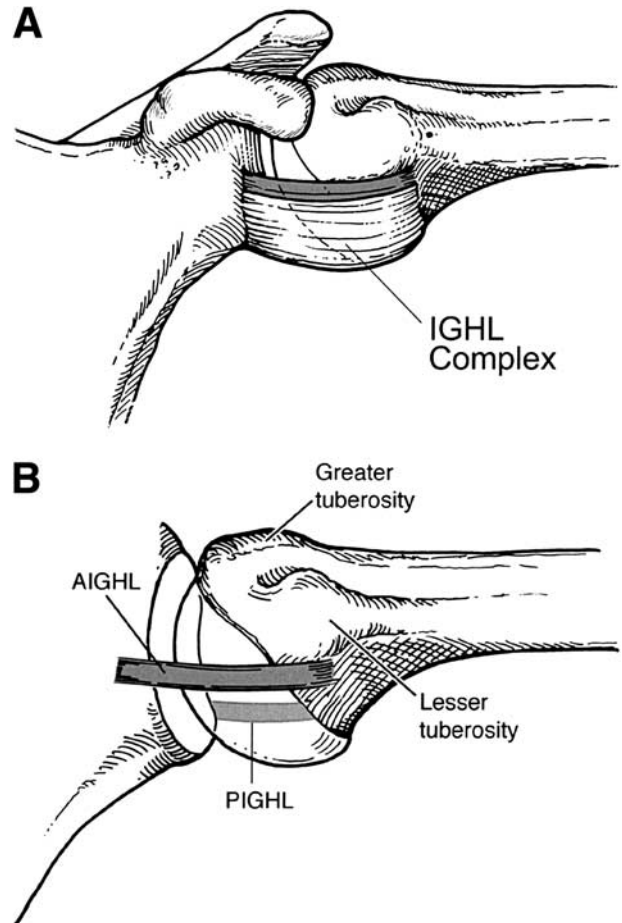


FIGURE 8. (A) The hammock of the IGHL complex. (B) The IGHL complex can be mechanically modeled by representing its 2 dominant structures, the anterior and posterior bands, as interdependent cables (reciprocal cable model).

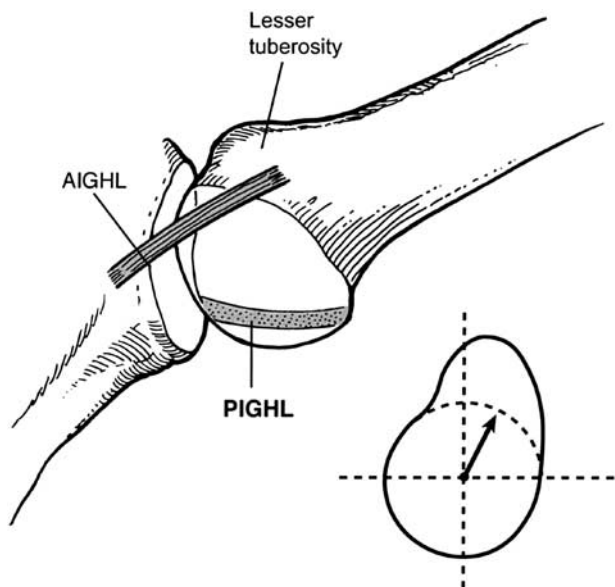


FIGURE 9. With abduction and external rotation, the 2 cables obliquely cross the shoulder as they reciprocally and equally develop tension. The center of rotation remains approximately at the glenoid bare spot and the greater tuberosity of the humerus has a well-defined circular arc (dotted line) before it contacts the posterior glenoid (internal impingement position).

potentially increased in the face of a shortened posterior band. The cam effect of the humeral head is also reduced, creating a relative redundancy in the antero-inferior capsule.

Recently, a study from the biomechanics laboratory at Temple University used cadaveric shoulders tracked by electromagnetic sensors. They determined to within 1 mm the relationship of the humeral head to the articular surface of the glenoid.³⁵ These investigators placed the shoulders in maximum abduction and external rotation and evaluated the glenohumeral spatial relationships in this position both before and after posteroinferior capsular plication. Their results clearly documented a posterosuperior shift of the humeral head on the glenoid face of approximately 4.4 mm in the presence of a posteroinferior capsular plication.

Hyperexternal Rotation of the Humerus: Tuberosity Clearance and Minimization of the Cam Effect

There are 2 mechanisms by which a tight posteroinferior capsule allows hyperexternal rotation of the humerus. First, the tethering effect of the shortened posterior capsule shifts the glenohumeral contact point posterosuperiorly, allowing the greater tuberosity to clear the glenoid rim through a greater arc of external

rotation before internal impingement occurs (Fig 10). Second, the shift in the glenohumeral contact point minimizes the cam effect of the proximal humerus on the antero-inferior capsule to allow greater external rotation due to the redundancy in the capsule (Fig 11).

To understand this cam effect, one must recognize that combined abduction and external rotation causes the antero-inferior capsule to drape tightly across the protuberant inferior articular surface of the humerus, which is quite prominent due to its location adjacent to the arc of the humeral calcar. When the contact point is shifted posterosuperiorly in a thrower's shoulder, the cam effect of the humeral head is dramatically decreased. As a result, the antero-inferior capsule is no longer tightly draped across a protruding humeral head (Fig 11). The loosened capsule is, in effect, functionally lengthened by virtue of the change in position of the contact point, allowing a greater degree of external rotation. One author (S.S.B.) has confirmed anatomically the functional lengthening of the capsule that occurs with a posterosuperior shift of the glenohumeral contact point (unpublished data).

Crockett et al.³⁶ noted increased humeral retroversion in the dominant shoulders of professional baseball pitchers in association with increased external rotation at 90° abduction. This finding is not surpris-

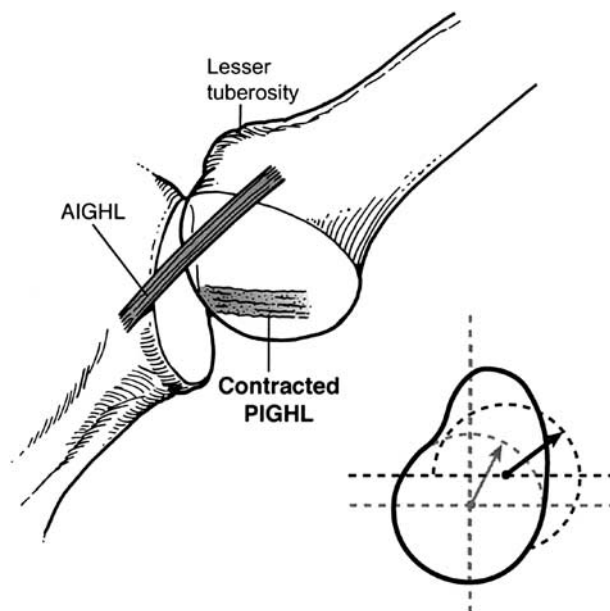


FIGURE 10. When the posterior cable shortens (contracted posterior band), the glenohumeral contact point shifts posterosuperiorly and the allowable arc of external rotation (before the greater tuberosity contacts the posterior glenoid) significantly increases (dotted lines).

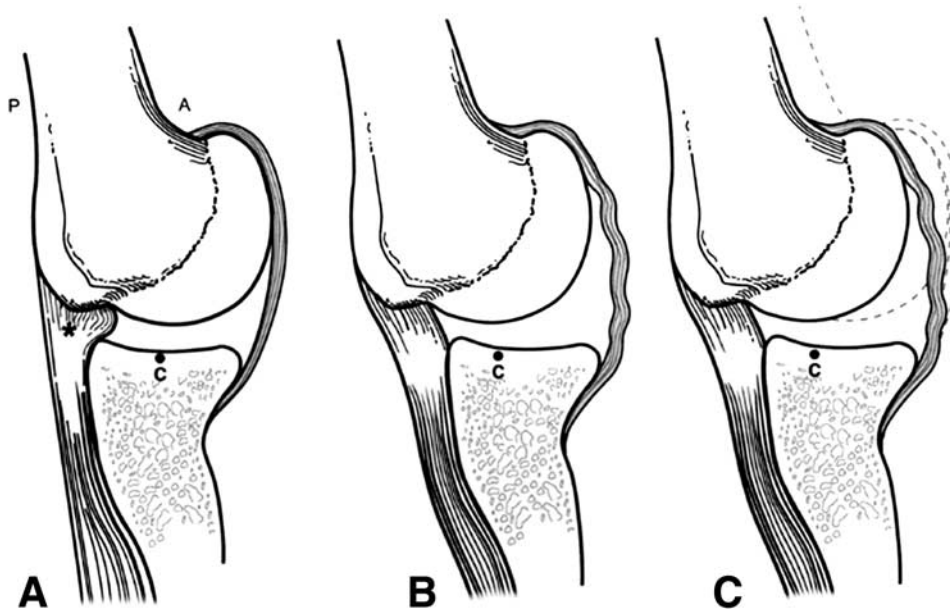


FIGURE 11. (A) With the arm in a position of abduction and external rotation, the humeral head and the proximal humeral calcar produce a significant cam effect of the anteroinferior capsule, tensioning the capsule by virtue of the space-occupying effect. (B) With a posterosuperior shift of the glenohumeral contact point, the space-occupying effect of the proximal humerus on the anteroinferior capsule is reduced (reduction of cam effect). This creates a relative redundancy in the anteroinferior capsule that has probably been misinterpreted in the past as microinstability. (C) Superimposed neutral position (dotted line) shows the magnitude of the capsular redundancy that occurs as a result of the shift in the glenohumeral contact point.

ing, because increasing degrees of humeral retroversion will decrease the cam effect and will also allow for greater clearance of the greater tuberosity over the edge of the glenoid to permit hyperexternal rotation.

We agree with Halbrecht et al.²² that anterior instability is not generally a part of the pathology in the throwing shoulder. The apparent increased anterior laxity may simply be a consequence of the reduction in the cam effect with the functional lengthening of the anteroinferior capsuloligamentous complex, in conjunction with pseudolaxity caused by a posterior SLAP lesion. Furthermore, all or part of the hyperexternal rotation may be due to the functional lengthening of the IGHL that occurs when the glenohumeral contact point shifts posterosuperiorly due to a tight posteroinferior capsule. However, over time, chronic hyperexternal rotation in conjunction with a protracted scapula may stretch the IGHL to some extent.³⁷

This stretching differs from the standard type of anterior instability in that the capsuloligamentous structures are overloaded by tensile forces from excessive humeral external rotation rather than by shear forces from anterior humeral translation. However, if the thrower externally rotates far enough with the arm abducted 90°, he may reach the provocative position for production of an anteroinferior subluxation or dislocation, tearing the anterior capsuloligamentous complex. We have seen late breakdown anteriorly with IGHL disruption in only a couple of instances in older

throwers with chronic symptoms, but never in the younger pitchers with the dead arm. We believe that true instability is rare and that it develops slowly over time. Therefore it only manifests itself in veteran pitchers. The hyperexternal rotation associated with the shift in the glenohumeral contact point in the older thrower may contribute to the pseudolaxity associated with SLAP lesions.

We agree with the observation by Walch et al.¹⁴ that all shoulders exhibit internal impingement in the abducted and externally rotated position and that therefore internal impingement should ordinarily not be considered pathologic. The exception to this view is the thrower that hyperexternally rotates his arm during the late cocking phase (Fig 12), achieving maximal external rotation in excess of 130°. Athletes in this category are usually the older elite throwers, and the hyperexternal rotation that they achieve can cause excessive abrasion of the cuff against the posterosuperior glenoid, resulting in damage to the cuff.

An even greater adverse effect of hyperexternal rotation on the rotator cuff is that it allows repetitive hypertwisting of the rotator cuff fibers (Fig 13). This hypertwist phenomenon can lead to torsional overload and shear failure of cuff fibers. With the arm in the abducted and externally rotated position, the greatest shear stresses in the cuff will be at their articular-side attachment, which is the location where cuff failure occurs in the thrower (Fig 14).




FIGURE 12. These baseball pitchers, in the late cocking phase of throwing, have maximized their external rotation.

The External Rotation Set Point

Maximum internal rotation velocity in the elite pitcher is approximately 7,000°/second, perhaps the fastest human motion in all of sport.³⁹ In the tennis serve, researchers have shown that the greatest contribution to racket head speed at ball impact is produced by internal rotation of the shoulder.^{40,41} We know that other contributions from forces and interactive moments at various points within the kinetic chain are important,⁴² but maximizing internal rota-

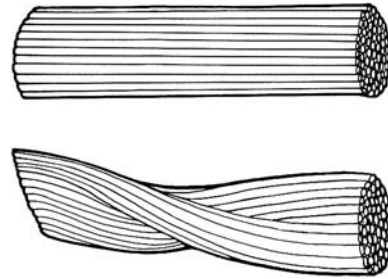


FIGURE 13. The rotator cuff can be considered as a collection of fiber bundles that undergo significant torsional and shear stresses as the shoulder internally and externally rotates.

tion velocity is of extreme importance to the thrower.⁴³

The most effective way to maximize internal rotation velocity is to maximize the arc of rotation by means of hyperexternal rotation in late cocking. The longer the arc of rotation through which angular acceleration is achieved, the greater the velocity of the hand, and therefore the greater the velocity of the baseball at ball release.

High-level pitchers appear to have a set point of external rotation that they know they must achieve to throw hard. Elite pitchers have a proprioceptive sense of reaching their set point of external rotation, which they call the slot. They know that if they cannot reach the slot, they will not be able to throw with their maximum velocity. If the glenohumeral contact point shifts, as it does with a tight posteroinferior capsule, the successful pitcher will be able to externally rotate back to his set point even more effectively. The teth-

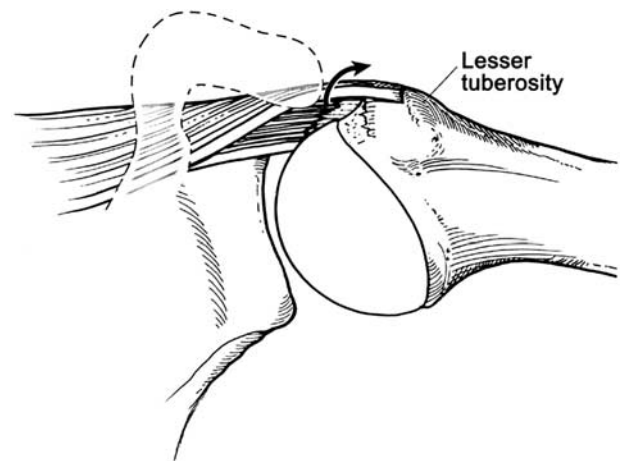


FIGURE 14. Torsional overload with repetitive hypertwisting of rotator cuff fibers occurs on the articular surface of the rotator cuff, the most common location of cuff failure in the thrower.

ering effect of the posteroinferior capsule, with the concomitant shift of the glenohumeral contact point, allows clearance of the greater tuberosity to achieve a greater arc of external rotation. As a result, internal impingement does not occur until the shoulder achieves a position of hyperexternal rotation. Furthermore, posterosuperior shift of the glenohumeral contact point lessens the cam effect of the proximal humerus in abduction and external rotation, achieving a functional lengthening of the anteroinferior capsule that permits greater external rotation.

Pitchers with a tight posteroinferior capsule and GIRD know that they must reach their set point of external rotation, and they will find a way to do it even though the deranged mechanics predispose to superior labral injury by virtue of increased peel-back forces and increased shear forces on the labrum. Such pitchers are constantly on the brink of injury. In this type of overhead athlete, the thinking brain recognizes that the arm must be brought back to a certain position (the set point), and the acting brain finds a way to get it there.

High-level overhead athletes have been shown to combine ballistic and tracking modes in achieving control with high velocity.⁴⁴ Ballistic movement is an automatic movement under preprogrammed neural control (such as externally rotating to the set point) that can be modified and facilitated by muscle activation in response to feedback from receptors on muscles and tendons (tracking mode) to fine-tune the control aspect of throwing a ball to a specific target point. These preprogrammed patterns start from the legs and trunk, then proceed to the scapular stabilizers and arm positioners for force generation. From there, these patterns are coordinated at the elbow and wrist for pitch control.

Peel-Back Mechanism

We have observed a dynamic peel-back phenomenon¹⁶ arthroscopically in throwers with posterior and combined anteroposterior SLAP lesions. The peel-back occurs with the arm in the cocked position of abduction and external rotation and is due to the effect of the biceps tendon as its vector shifts to a more posterior position in late cocking. At arthroscopy, when the arm is removed from traction and brought into abduction and external rotation, the biceps tendon can be seen to assume a more vertical and posterior angle (Fig 15). This dynamic angle change produces a posterior shift in the biceps vector as well as a twist at the base of the biceps, which then transmits a torsional

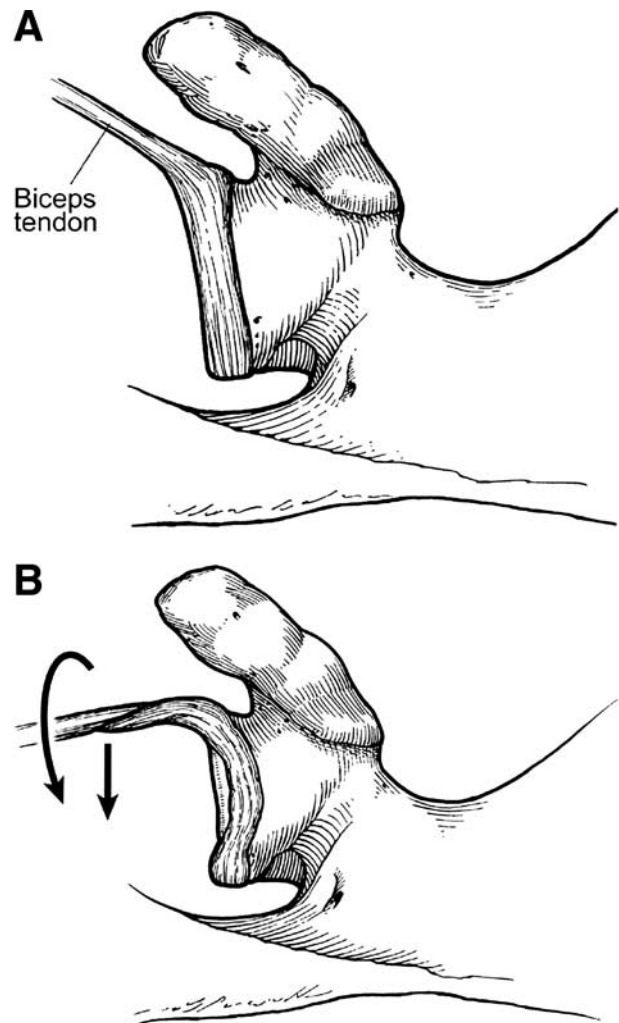


FIGURE 15. (A) Superior view of the biceps and labral complex of a left shoulder in a resting position. (B) Superior view of the biceps and labral complex of a left shoulder in the abducted, externally rotated position, showing peel-back mechanism as the biceps vector shifts posteriorly.

force to the posterior superior labrum. If the superior labrum is not well-anchored to the glenoid, this posteriorly directed torsional force will cause it to rotate medially over the corner of the glenoid onto the posterosuperior scapular neck. In addition, the biceps root will shift medial to the supraglenoid tubercle (Fig 16).

This peel-back phenomenon is a consistent finding in patients with posterior SLAP lesions or combined anteroposterior SLAP lesions, and it is absent in normal shoulders and in some anterior SLAP lesions that do not have extension into the posterosuperior quadrant. However, anterior SLAP lesions without a de-

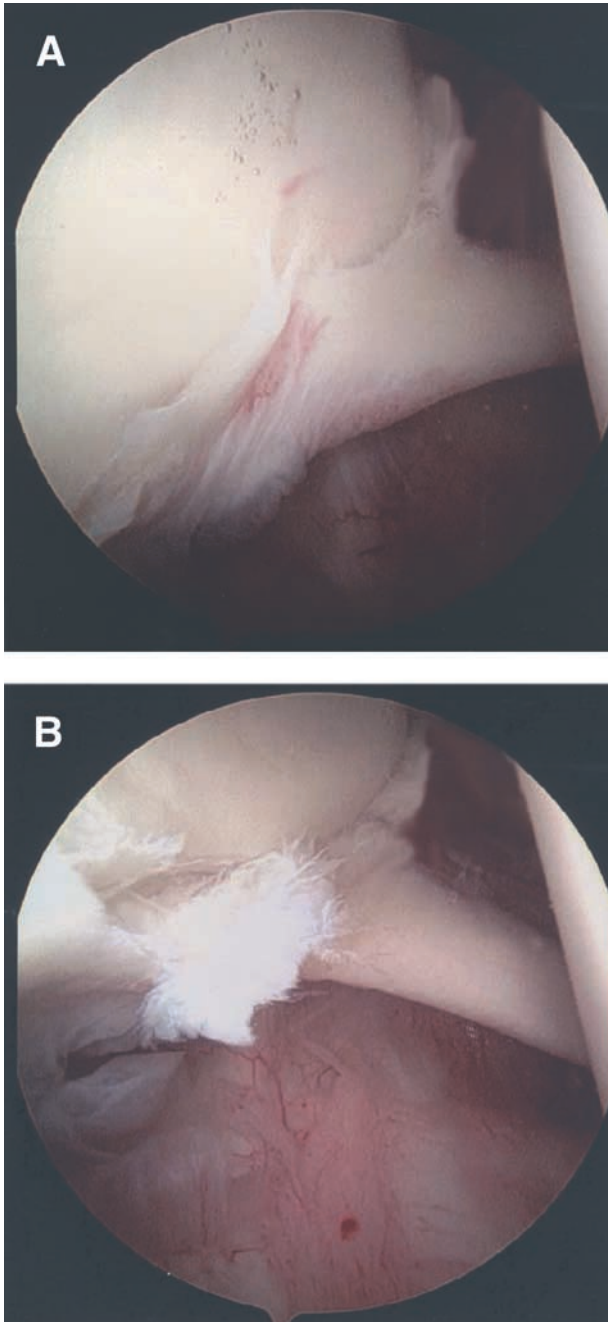


FIGURE 16. (A) In this left shoulder in the resting (neutral) position, the posterosuperior labrum covers the corner of the glenoid. (B) The arthroscopic view of the same shoulder in abduction and external rotation, which has caused the posterosuperior glenoid labrum to be peeled back and medially shifted over the corner of the glenoid.

monstrable peel-back sign are not usually seen in throwers. The typical “thrower’s SLAP” has posterior extension of the lesion and a positive peel-back sign.

A successful SLAP repair in a throwing athlete

must eliminate the peel-back sign as evidence that this torsional force has been neutralized. A suture anchor with a simple suture loop around the labrum develops tensile forces within the suture loop to efficiently and effectively resist the torsional force of the peel-back mechanism. However, translabral tacks are mechanically less effective in resisting the torsional peel-back because they have only a single point of contact at the periphery of the labrum.⁴⁵ Morgan et al.¹ reported a 97% success rate with suture anchors compared with reported success rates ranging from 71% to 88% with absorbable translabral tacks.⁴⁶⁻⁴⁹ This higher success rate for the suture anchor technique is not surprising in view of the superior mechanical characteristics of suture anchors in resisting torsional forces.

Acceleration Versus Deceleration Injury

Andrews et al.¹⁰ postulated a deceleration mechanism for labral injuries in throwers as the biceps contracts to slow down the rapidly extending elbow in follow through. They suggested that this mechanism creates a high tensile load in the biceps that acts to pull the biceps and superior labrum complex from the bone. In contrast, we have postulated an acceleration mechanism. In fact, we have found that throwers who recall the pitch that caused their injury invariably relate the severe sudden onset of pain to the abducted and externally rotated position of late cocking, as the arm begins to accelerate forward.

Kuhn et al.⁵⁰ performed an experimental comparison of these 2 mechanisms (acceleration and deceleration) in a cadaver model. To simulate the deceleration mechanism, they applied a tensile force through the biceps with the arm in the follow-through position. They were able to produce a superior labral avulsion in only 20% of specimens, and only with a large tensile force (346 ± 40 N). To simulate the acceleration mechanism, they loaded the biceps of cadaver specimens in the abducted, externally rotated position of late cocking and consistently produced a type 2 SLAP lesion at a force of 289 ± 39 N, 20% less than the force required to produce a SLAP lesion by the deceleration mechanism. Importantly, they were able to produce type 2 SLAP lesions in 9 of 10 specimens in the abducted, externally rotated position and in only 2 of 10 of those in the deceleration position ($P = .055$). In view of this clinical and experimental evidence, we believe that the biceps and superior labrum complex is not pulled from bone, but rather is peeled from bone.

THE PATHOLOGIC CASCADE

We believe that the acquired posteroinferior capsular contracture is the first and essential abnormality that initiates a pathologic cascade that climaxes in the late cocking phase of throwing. At that point, the shift in the glenohumeral contact point causes maximum shear stress on the posterosuperior labrum at exactly the time when the peel-back force and the total force being funneled into the shoulder by the kinetic chain are both at a maximum. This combination of factors puts the shoulder in a very vulnerable situation.

In the presence of a contracted or shortened posterior band of the IGHL complex, the inferior axillary pouch structures are imbalanced and will not allow the normal cradling or hammock effect described by O'Brien et al.³¹ This effect normally allows the shoulder to wind and unwind in abduction around a relatively fixed central glenohumeral rotation point located in the lower half of the glenoid face. Arthroscopists have called this the bare spot. As the shoulder attempts to wind up into the cocked position, the contracted posterior band will not allow the head to fully externally rotate around the normal glenoid rotation point. It acts as a rein or tether that draws the humeral head posterosuperiorly to a new rotation point on the glenoid.³⁵

Furthermore, in abduction and external rotation, the tight posterior band of the IGHL is now bowstrung beneath the humeral head, exerting a posterosuperiorly directed force that maintains the shift of the rotation point (Fig 17). Once this posterosuperior shift has occurred, the humeral head can then abnormally excessively externally rotate around the new rotation point because the rotation shift relaxes the anterior capsule due to the decreased cam effect of the humeral calcar such that the thrower can externally rotate beyond his usual set point in the fully cocked position (Fig 11).

As the shoulder now abducts and excessively externally rotates around this new pathologic posterosuperior rotation point, a number of adverse consequences occur. (1) Shear forces at the biceps anchor and the posterosuperior labral attachment increase, and both structures begin to fail from their attachments via the peel back mechanism that produces a posterior type 2 SLAP lesion.¹⁶ (2) The anterior capsular structures, which were normal and appropriately tensioned before the shift occurred, become lax in the new rotation axis for any given amount of true glenohumeral external rotation due to a reduction in the cam effect. The glenohumeral rotation may be excessive, causing hyperexternal rotation with increased tensile stresses on

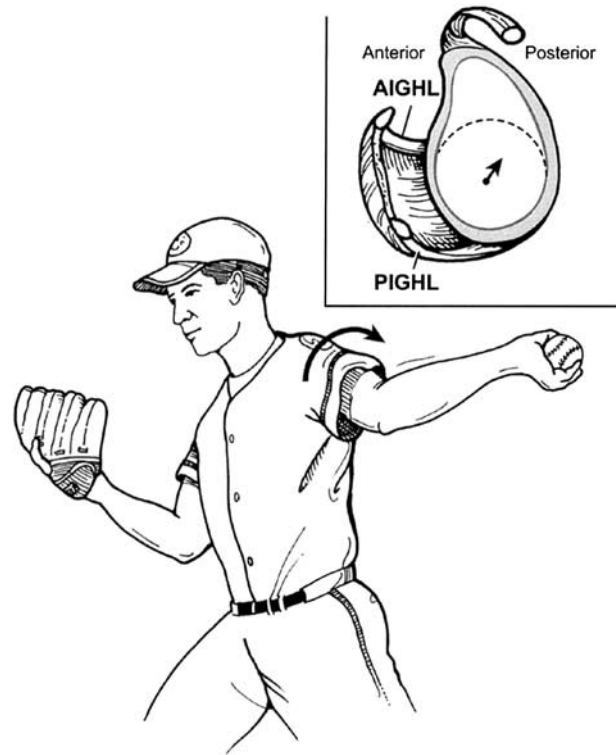


FIGURE 17. In abduction and external rotation (late cocking), the posterior band of the IGHL is bowstrung beneath the humeral head, causing a posterosuperior shift in the glenohumeral rotation point. Also in late cocking, the biceps vector shifts posteriorly and twists at its base, maximizing peel-back forces. As a result of the tight posteroinferior capsule, this pitcher shows classic derangements of pitching mechanics: hyper-external rotation, hyper horizontal abduction (out of the scapular plane), dropped elbow, and premature trunk rotation.

the IGHL such that, if the patient continues to throw, the anterior capsule may begin to fail either in continuity or at the labrum in the Bankart zone as a tertiary problem. (3) Excessive external rotation caused by GIRD as described previously also causes increased shear and torsional stresses in the posterosuperior rotator cuff. This presents as undersurface fiber failure as reported by Jobe¹⁵ and Morgan et al.¹

All of these consequences are worsened by a protracted scapula that antetilt the glenoid, increasing anterior tensile loads on the capsule and increasing the peel-back effect posteriorly. Thus, once the SLAP event has occurred, the posterosuperior shift and hyperexternal rotation are magnified, and the pathologic cascade continues. This is all because of an acquired posteroinferior capsular contracture, which may have been clinically silent initially.

Production of the SLAP Lesion: the Coup De Grâce

Physicians must always remember the dynamic nature of this biomechanical system and the forces that act on the labrum. When the shoulder goes into a position of abduction and external rotation, the posterior band of the IGHL is brought beneath the humeral head. If the posteroinferior capsule is contracted and tight, it will bowstring under the humeral head, pushing the humerus posterosuperiorly into the posterosuperior labrum. This labral shear force is at a maximum with the arm in the cocked position of abduction and external rotation, and this is also the exact position at which the peel-back forces are maximized (Fig 18). Furthermore, the cocked position is the point in the throwing cycle in which energy from the trunk is being transmitted to the shoulder to help accelerate the arm. This scenario of maximum superior labral shear force combined with maximum peel-back force at the exact moment that maximum acceleration forces are being funneled into the shoulder by the kinetic chain

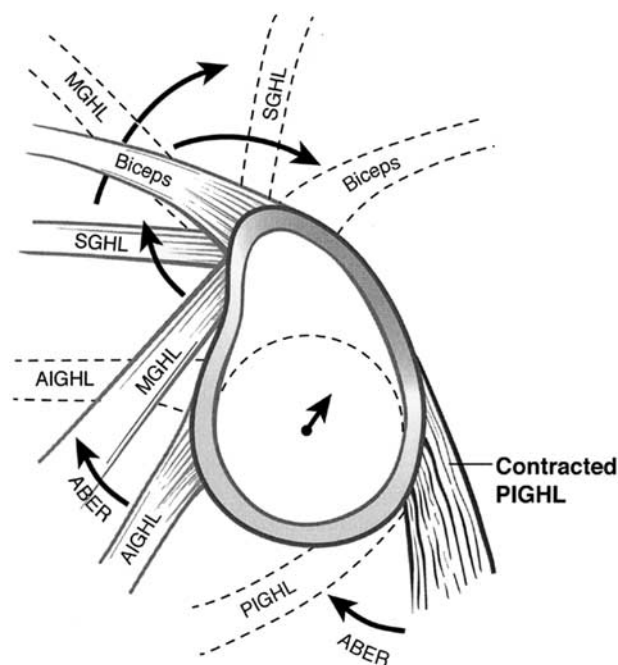


FIGURE 18. This diagram shows the shift in position that occurs in the major tendon and capsuloligamentous structures of the glenohumeral joint between the resting position (solid lines) and the abducted-externally rotated position (dotted lines). In abduction and external rotation, the bowstrung posterior band of the IGHL (PIGHL) is beneath the humeral head, causing a shift in the glenohumeral rotation point; and the biceps vector shifts posteriorly as the peel-back forces are maximized.

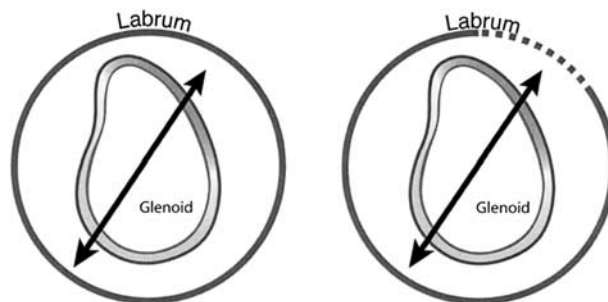


FIGURE 19. Circle concept of pseudolaxity. With a break in the labral ring, there is a channeling effect of apparent laxity to the opposite side of the ring where there is no disruption. Repair of the labral disruption eliminates the pseudolaxity. Pseudolaxity from a break in the labral ring is augmented by reduction of the cam effect that occurs when the glenohumeral contact point shifts posterosuperiorly.

creates a potentially disastrous situation for the “shoulder-at-risk.”

INSTABILITY VERSUS PSEUDOLAXITY: THE “CIRCLE CONCEPT”

Previous reports have suggested that anterior instability is the primary cause of the dead arm syndrome. We disagree. Even so, the surgeon generally encounters a positive drive-through sign (in which he or she can drive the scope from top to bottom of the glenohumeral joint without significant resistance) in association with type 2 SLAP lesions.

This sign does not necessarily indicate anteroinferior instability but may simply indicate a pseudolaxity that occurs with a posterosuperior break in the labral ring. Disruption of the labral attachment on one side of the glenoid allows channeling of laxity to the opposite side of the ring (circle concept) (Fig 19). Furthermore, if the glenohumeral contact point shifts posterosuperiorly, the cam effect of the humeral head on the anterior capsule will be reduced, producing a relative capsular redundancy that can be misinterpreted as instability. This pseudolaxity is eliminated by SLAP repair in almost all cases, as indicated by restoration of normal resistance to drive-through after repair.

We believe that pseudolaxity (due to reduction of the cam effect and a break in the labral ring) has been incorrectly identified in the past as anteroinferior instability. Furthermore, we believe that this misidentification has perpetuated instability surgery as treatment for the dead arm and has delayed recognition of the SLAP lesion in association with the contracted posteroinferior capsule as the usual cause of this syndrome.

We suspect that the limited success of the Jobe anterior capsulolabral repair in some throwers has been due to its ability to create an anteroinferior capsular contracture that matched the posteroinferior capsular contracture, thereby reducing the posterosuperior shift of the glenohumeral contact point that begins the pathologic cascade to the dead arm. During postoperative rehabilitation, patients with these injuries would begin with a symmetrically over-tightened shoulder that could then be symmetrically stretched during rehabilitation. Although such an approach can be successful, the morbidity is significantly greater and the predictability is much lower than with our approach.

Associated Rotator Cuff Tears

We found rotator cuff tears in 31% of throwers with SLAP lesions¹; 38% of these tears were full thickness and 62% were partial-thickness. The full-thickness tears were located in the midportion of the rotator crescent, with varying degrees of anterior and posterior extension. The partial-thickness cuff tears were in lesion-specific anatomic locations; that is, the anterior SLAP lesions were associated with partial-thickness articular-surface rotator cuff tears in the anterior portion of the rotator crescent, and the posterior SLAP lesions were associated with partial-thickness articular surface rotator cuff tears in the posterior portion of the rotator crescent.

Because of the location specificity of the partial-thickness cuff tears, we believe that repetitive tensile loading of specific areas of the cuff may occur caused by superior subluxation of the humerus in combination with repetitive torsional loading from hyperexternal rotation. For posterior type 2 SLAP lesions, we believe that the humerus subluxes posterosuperiorly because of the break in the labral ring, repetitively producing high tensile forces in the posterosuperior cuff. These forces may ultimately contribute to tearing of the rotator cuff tear. In addition, the hypertwist phenomenon caused by hyperexternal rotation of the shoulder can lead to torsional and shear overload with fatigue failure of cuff fibers in this same area of the posterosuperior cuff (Fig 14).

THE ULTIMATE CULPRIT

We believe that the culprits in development of the dead arm are (1) a tight posteroinferior capsule causing a GIRD and a shift in the glenohumeral rotation point; (2) peel-back forces causing the SLAP lesion;

(3) hyper-external rotation of the humerus because of a reduction in the humeral cam effect on the anterior capsule and clearance of the greater tuberosity over the glenoid rim through a larger arc of external rotation before internal impingement occurs; and (4) scapular protraction. Of these, the ultimate culprit that starts the pathologic cascade is the tight posteroinferior capsule. If we could prevent this from developing, we could prevent the dead arm.

What causes the tight posteroinferior capsule? We believe that the most likely explanation is that the thickening and contracture of the posteroinferior capsule occurs in response to the loads that act on it during follow-through. After ball release, the arm moves ahead of the body and exerts a large distraction force of approximately 750 N (about 80% of the pitcher's body weight)³⁸ that acts on the posteroinferior capsule. At that point in the follow-through, the elbow is fully extended so that no moments are exerted on the glenohumeral joint; the load is one of a pure distraction force. Because the shoulder is internally rotated in follow-through, the inferior part of the posterior capsule is rotated into a more posterocentral position, where it more directly resists the distraction force of follow-through (Fig 20). The shoulder musculature provides a compressive force to resist this distraction force, but the capsule undoubtedly is subjected to repetitive high loads that cannot be com-

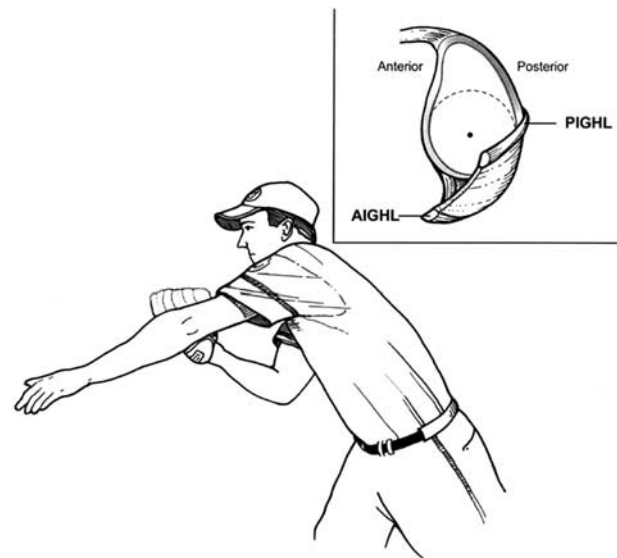


FIGURE 20. During follow-through, large distraction forces (80% of the pitcher's body weight) must be resisted by the posteroinferior capsule. The capsule has rotated into a posterocentral location, where it can most effectively resist these distraction forces of follow-through.

pletely resisted by the muscle forces. This repetitive tensile loading of the posteroinferior capsule could cause the capsular hypertrophy that is so common in throwing athletes. If this is the etiology of the thickened capsule, there may be nothing we can do to completely prevent it. Strengthening the rotator cuff and posterior shoulder musculature to resist the distraction force and minimize the load on the capsule should be beneficial, but repetitive loading in the follow-through phase will still probably cause some degree of adaptive hypertrophy of the posteroinferior capsule. Ironically, the inability to accelerate the ball in the dead arm syndrome may ultimately be due to the inability of the muscles to effectively decelerate the arm in follow-through.

Editor's Note: Part II: Evaluation and Treatment of SLAP Lesions in Throwers will appear in Vol. 19, No. 5, and Part III: The "SICK" Scapula, Scapular Dyskinesis, the Kinetic Chain, and Rehabilitation will appear in Vol. 19, No. 6.

Acknowledgment: The authors thank Jeff Cooper, P.T., A.T.C. (Head Athletic Trainer, Philadelphia Phillies) and Phil Donley, P.T., A.T.C., M.S. (consultant, Philadelphia Phillies) for their assistance in the preparation of this paper.

REFERENCES

- Morgan CD, Burkhart SS, Palmeri M, et al. Type II SLAP lesions: Three subtypes and their relationship to superior instability and rotator cuff tears. *Arthroscopy* 1998;14:553-565.
- Burkhart SS, Morgan CD. SLAP lesions in the overhead athlete. *Orthop Clin North Am* 2001;32:431-441.
- Rowe CR, Pierce DS, Clark DG. Voluntary dislocation of the shoulder. *J Bone Joint Surg Am* 1973;55:445-410.
- Bennett GE. Elbow and shoulder dislocations of baseball players. *Am J Surg* 1959;98:484-488.
- Lombardo SJ, Jobe FW, Kerlan RK, et al. Posterior shoulder lesions in throwing athletes. *Am J Sports Med* 1977;5:106-110.
- Tibone JE, Jobe FW, Kerlan RF, et al. Shoulder impingement syndrome in athletes treated by anterior acromioplasty. *Clin Orthop* 1985;188:134-140.
- Kennedy JC, Hawkins RJ, Krusoff WB. Orthopedic manifestations of swimming. *Am J Sports Med* 1978;6:309-327.
- Pery J. Anatomy and biomechanics of the shoulder in throwing, swimming, gymnastics, and tennis: Symposium on injuries to the shoulder in the athlete. *Clin Sports Med* 1983;2:247-270.
- Tibone JE, Elrod B, Jobe FW, et al. Surgical treatment of tears of the rotator cuff in athletes. *J Bone Joint Surg Am* 1986;68:887-891.
- Andrews JR, Carson W Jr., McLeod W. Glenoid labrum tears related to the long head of the biceps. *Am J Sports Med* 1985;13:337-341.
- Cook FF, Tibone JE. The Mumford procedure in athletes: An objective analysis of function. *Am J Sports Med* 1988;16:97-100.
- Garth WP, Allman FL, Armstrong WS. Occult anterior subluxation of the shoulder. *Am J Sports Med* 1987;15:579-585.
- Jobe FW, Tibone JE, Jobe CM, et al. The shoulder in sports. In: Rockwood CA Jr., Matsen FA III, eds. *The Shoulder*. Philadelphia: WB Saunders, 1990;963-967.
- Walch G, Boileau J, Noel E, et al. Impingement of the deep surface of the supraspinatus tendon on the posterior superior glenoid rim: An arthroscopic study. *J Shoulder Elbow Surg* 1992;1:238-243.
- Jobe CM. Posterior superior glenoid impingement: Expanded spectrum. *Arthroscopy* 1995;11:530-537.
- Burkhart SS, Morgan CD. Technical note: The peel-back mechanism. Its role in producing and extending posterior type II SLAP lesions and its effect on SLAP repair rehabilitation. *Arthroscopy* 1998;14:637-640.
- Snyder SJ, Karzel RP, Delpizzo W, et al. SLAP lesions of the shoulder. *Arthroscopy* 1990;6:274-279.
- Snyder SJ, Banas MP, Karzel RP. An analysis of 140 injuries to the superior glenoid labrum. *J Shoulder Elbow Surg* 1995;4:243-248.
- Burkhart SS, Morgan CD, Kibler WB. Shoulder injuries in overhead athletes. *Clin Sports Med* 2000;19:125-158.
- Jobe FW, Giangarra CE, Kvitne RS, et al. Anterior capsulolabral reconstruction of the shoulder in athletes in overhead sports. *Am J Sports Med* 1991;19:428-434.
- Rubenstein DL, Jobe FW, Glousman RE, et al. Anterior capsulolabral reconstruction of the shoulder in athletes. *J Shoulder Elbow Surg* 1992;1:229-237.
- Halbrecht JL, Tirman P, Atkin D. Internal impingement of the shoulder: Comparison of findings between the throwing and nonthrowing shoulders of college baseball players. *Arthroscopy* 1999;15:253-258.
- Garth WP, Allman FL, Armstrong NS. Occult anterior subluxation of the shoulder. *Am J Sports Med* 1987;15:579-585.
- Kvitne RS, Jobe FW. The diagnosis and treatment of anterior instability in the throwing athlete. *Clin Orthop* 1993;291:107-123.
- Jobe CM, Pink MM, Jobe FW, Shaffer B. Anterior shoulder instability, impingement, and rotator cuff tear: Theories and concepts. In: Jobe FW, ed. *Operative techniques in upper extremity sports injuries*. St. Louis: Mosby, 1996;164-176.
- Glousman RE, Jobe FW. Anterior shoulder instability: Impingement and rotator cuff tear. Anterior and multidirectional instability. In: Jobe FW, ed. *Operative techniques in upper extremity sports injuries*. St. Louis: Mosby, 1996;191-209.
- Verna C. Shoulder flexibility to reduce impingement. Presented at the 3rd Annual PBATS (Professional Baseball Athletic Trainer Society) Meeting, Mesa, Arizona, March, 1991.
- Morgan CD. The thrower's shoulder. In: McGinty JB, ed. *Operative arthroscopy*. Ed 3. Philadelphia: Lippincott, 2003; 570-584.
- Kibler WB. SLAP lesions and their relationship to glenohumeral internal rotation deficit. *Am J Sports Med* (submitted).
- Kibler WB. The relationship of glenohumeral internal rotation deficit to shoulder and elbow injuries in tennis players: A prospective evaluation of posterior capsular stretching. Presented at the Annual closed meeting of the American Shoulder and Elbow Surgeons, New York, October 1998.
- O'Brien SJ, Neves MC, Arnoczky SP, et al. The anatomy and histology of the inferior glenohumeral ligament complex of the shoulder. *Am J Sports Med* 1990;18:449-456.
- Leet KM. *Fundamentals of structural analysis*. New York: MacMillan Publishing, 1988;138.
- Huson A. Biomechanische probleme des kniiegelenks. *Orthopade* 1974;3:119-126.
- Menschik A. Mechanik des kniiegelenks: Teil 1. *Z Orthop* 1974;113:481-495.
- Koffler KM, Bader D, Eager M, et al. The effect of posterior capsule tightness on glenohumeral translation in the late cocking phase of pitching: A cadaveric study. The 21st Annual Meeting of the Arthroscopy Association of North America, Washington, DC, April 25, 2002.

36. Crockett HC, Gross LB, Wilk KE, et al. Osseous adaptation and range of motion at the glenohumeral joint in professional baseball pitchers. *Am J Sports Med* 2002;30:20-26.
37. Weiser WM, Lee TQ, McMaster WC. Effects of simulated scapular protraction on anterior glenohumeral stability. *Am J Sports Med* 1999;27:801-805.
38. Levitz CL, Dugas J, Andrews JR. The use of arthroscopic thermal capsulorrhaphy to treat internal impingement in baseball players. *Arthroscopy* 2001;17:573-577.
39. Fleisig GS, Dillman CJ, Andrews JR. Biomechanics of the shoulder during throwing. In: Andrews JR, Wilk KE, eds. *The athlete's shoulder*. New York: Churchill Livingstone, 1994;360-365.
40. Springs E, Marshall R, Elliot B, Jennings L. A three-dimensional kinematic method for determining the effectiveness of arm segment rotations in producing racquet-head speed. *J Biomech* 1994;27:245-254.
41. Marshall RN, Elliott BC. Long-axis rotation: The missing link in proximal-to-distal segmental sequencing. *J Sports Sci* 2000; 18:247-254.
42. Putnam CA. Sequential motions of body segments in striking and throwing skills: Descriptions and explanations. *J Biomech* 1993;26:125-135.
43. Fleisig GS, Andrews JR, Dillman CJ, Escamilla RF. Kinetics of baseball pitching with implications about injury mechanisms. *Am J Sports Med* 1995;23:233-239.
44. Ariel GB, Braden VK. Biomechanical analysis of ballistic vs tracking movements in tennis skills. In: Groppe JL, ed. *Proceedings of the National Symposium on Racquet Sports*. Champaign, IL: University of Illinois, 1979;105.
45. Burkhart SS, Parten PM. Dead arm syndrome: Torsional SLAP lesions versus internal impingement. *Tech Shoulder Elbow Surg* 2001;2:74-84.
46. Pagnani MJ, Speer KP, Altchek DW, et al. Arthroscopic fixation of superior labral tears using a biodegradable implant: A preliminary report. *Arthroscopy* 1995;11:194-198.
47. Segmüller HE, Hayes MG, Saies AD. Arthroscopic repair of glenolabral injuries with an absorbable fixation device. *J Shoulder Elbow Surg* 1997;6:383-392.
48. Warner JJP, Kann S, Marks P. Arthroscopic repair of combined Bankart and superior labral detachment anterior and posterior lesions: Technique and preliminary results. *Arthroscopy* 1994;10:383-391.
49. Samani JE, Marston SB, Buss DD. Arthroscopic stabilization of type II SLAP lesions using an absorbable tack. *Arthroscopy* 2001;17:19-24.
50. Kuhn JED, Lindholm SR, Huston LJ, et al. Failure of the biceps-superior labral complex in the throwing athlete: A cadaveric biomechanical investigation comparing the positions of late cocking and early deceleration. The Arthroscopy Association of North America Specialty Day, AAOS Annual Meeting, Anaheim, California, February 7, 1999.